CLIA I.D. # 14D1075803
www.Hematogenix.com

Client Services: (888) Hemato-1
(708) 444-0444
Fax: (708) 444-0445

ACCESSION NUMBER: **BM10-10298**

PATIENT: **Doe, John**

Physician:	John Nice, M.D.	***D.O.B.*** 11/25/1932	***AGE:*** 77 yrs ***SEX:*** M
Facility:	Best Clinic	***Specimen Type:***	Bone Marrow
	1212 Main St.	***Date Collected:***	04/06/2010
	Good Town IN 46321	***Date Received:***	04/07/2010
Facility MR #	1234567	***Date Reported:***	04/12/2010

Clinical History:
Leukopenia (288.50), Thrombocytopenia (287.5), R/O MDS

BONE MARROW REPORT

DIAGNOSIS:

BONE MARROW CORE BIOPSY, CLOT SECTION, ASPIRATE SMEARS, TOUCH IMPRINTS AND PERIPHERAL BLOOD SMEAR:

-HYPERCELLULAR BONE MARROW WITH INCREASED MYELOBLASTS (~11-12%) AND DYSPOIESIS

-POSITIVE FOR 5q DELETION, TRISOMY 8 AND TRISOMY 13 BY FISH

-CONSISTENT WITH INVOLVEMENT BY A HIGH GRADE MYELODYSPLASTIC SYNDROME BEST CLASSIFIED AS REFRACTORY ANEMIA WITH EXCESS BLASTS-2 (RAEB-2)

-PLEASE SEE COMMENT

Comment:
The bone marrow is hypercellular for age with trilineal hematopoiesis and an increase in the number of blasts (~11-12%) based on CD34 stain of the core biopsy. The blasts have a myeloid phenotype by flow cytometry. In addition, dyserythropoiesis, dysgranulopoiesis and dysmegakaryopoiesis is noted with a slight increase in the number of monocytes in the bone marrow. Iron stains show increased storage iron with occasional ringed sideroblasts (<15%). FISH studies are positive for 5q deletion, trisomy 8 and trisomy 13 which portend an unfavorable prognosis. These findings are consistent with involvement by a high grade myelodysplastic syndrome best classified as refractory anemia with excess blasts-2 (RAEB-2). Clinical correlation and close follow-up are recommended.
Case discussed with Dr. Nice on 4-9-2010.

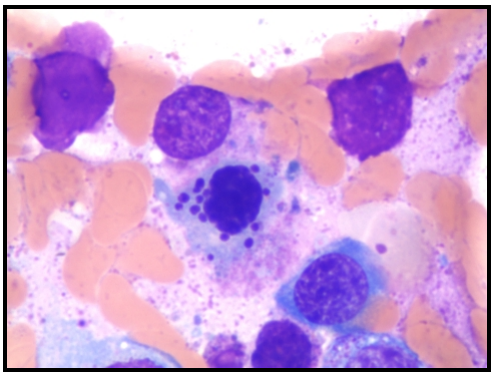
Dyserythropoiesis

Cytochemical and Immunohistochemical Stains:
CD34: increased blasts (~11-12%) with small cluster formation
CD117: increased immature myeloid cells
MPO: positive in blasts
CD68: slight increase in monocytes
CD3 and CD20: mixed B and T-cells with no lymphoid aggregates
Iron: increased storage iron with occasional ringed sideroblasts (<15%)

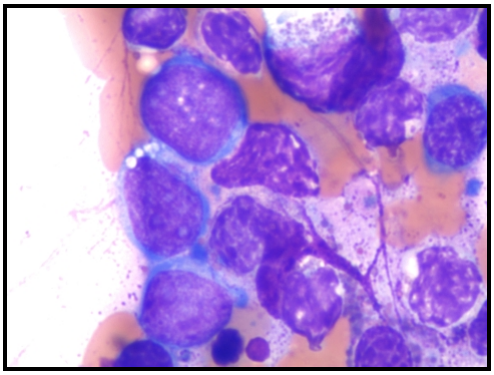
Increased blasts

Gross Description:

A. Received specimen in formalin labeled with patient's name. It consists of three core biopsies measuring 1.2, 0.6 and 0.4 cm in length. The specimen is submitted in cassette A after decalcification.

B. Specimen received in one container labeled with patient's name. It consists of a blood clot measuring 0.8 cm in greatest dimension. The specimen is submitted entirely in cassette B.

Hemogram Report
CBC Report provided by Best Clinic, dated 04/05/10.

	RESULT
WBC	5.1
Neutrophils	42.5%
Lymphocytes	50.2%
Monocytes	7.3%
Hemoglobin	10.0 g/dL (L)
Hematocrit	30.6% (L)
MCV	99.8 fL
RDW	21.4% (H)
MCH	32.7 pg (H)
MCHC	32.8 g/dL
Platelets	104,000 (L)

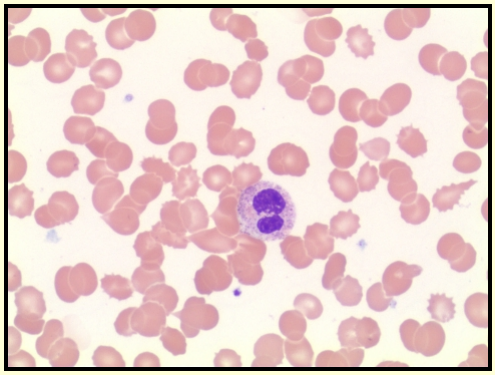
Hypolobated neutrophil

Peripheral Blood Smear: Macrocytic anemia with anisopoikilocytosis, rare circulating nucleated red blood cells. Hypolobated neutrophils (pseudo Pelger-Huet cells) with rare circulating blasts (~1%). Thrombocytopenia with occasional large and hypogranulated forms.

Bone Marrow Trephine Biopsy and Clot Section

	RESULT
Adequacy	Adequate
Cellularity	Hypercellular bone marrow for age (60-65% cellular)
Iron Stain	Increased storage iron
Myeloid Maturation	Increased blasts
Erythroid Maturation	Present
Blasts	Increased in number on CD34 stain with small clusters
Megakaryocytes	Few hypolobate forms noted

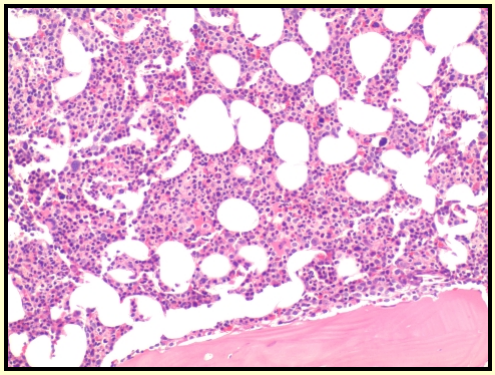
Hypercellular marrow

Bone Marrow Aspirate Smears

Cell Type	Result
Blasts	~8-10%, Increased in number (hemodilute aspirate smears)
Erythroid	31%, Dyserythropoiesis
Myeloid	50%, Dysgranulopoiesis
Monocytes	7%
Trilineage Hematopoiesis	Present
M:E Ratio	1.6:1
Iron Stain	Increased storage iron with occasional ringed sideroblasts (<15%)

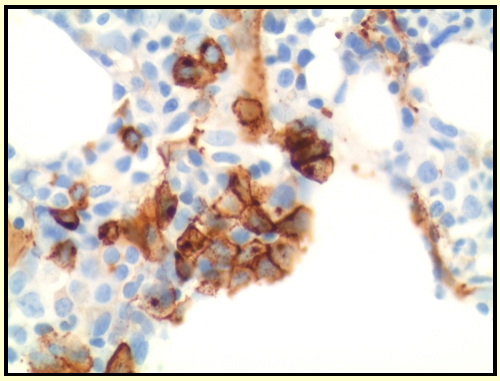

CD34: small cluster of blasts

Electronic Signature